

PATIENT

Froot Loop Spencer

PRESENTING CLINICAL SIGNS

History: Syncope/collapse. On pimobendan. Echo in 2024 (MML) showed CVD B2.
DIARY: Included.

SPECIES

Canine

BREED

Rat Terrier

SEX

MN

AGE

14 years

WEIGHT

8.8 lbs

INTERPRETED BY

Maggie Machen Lamy,
DVM, DACVIM
(Cardiology)

IMAGING PERFORMED BY

HOSPITAL NAME

WLAH

REFERRING VET

Dr. Kitz

INVOICE

45923

DATE

11/25/25

HOLTER MONITOR FINDINGS AND RHYTHM ASSESSMENT

| | |
|--------------------|---------------------|
| Time analyzed | 23:58h |
| Mean heart rate | 95bpm |
| Maximum heart rate | 216bpm |
| Minimum heart rate | 48bpm |
| VPCs | 173 singles, 1 pair |
| APCs | 133 singles |

Interpretation: Underlying normal sinus rhythm with appropriate HR variation. Max HR is sinus in origin. VPCs are seen, with a single couplet. Similar count of APCs are seen as well, singles only. AV block occasionally while sleeping. No sustained arrhythmias are observed.

Rhythm diagnosis: Sinus rhythm with VPCs and APCs.

INTERPRETATION OF THE FINDINGS & FURTHER RECOMMENDATIONS

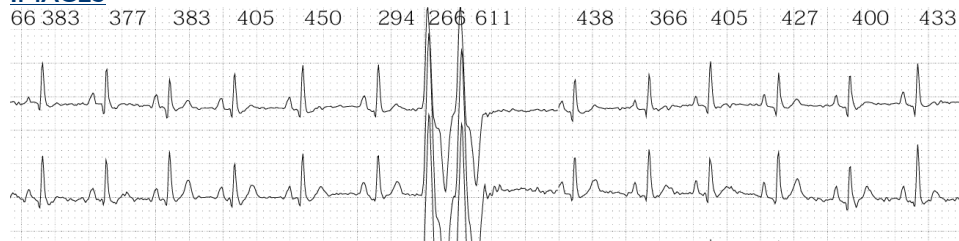The only abnormal finding is isolated APCs and VPCs. The overall count of each is similar (around 175), with low markers of malignancy. A single couplet is worth noting; however, this alone would not warrant therapy. A brief sinus pause is noted at 3:30pm; however, pet is asleep. Rare AV block while sleeping is also considered normal, and no obvious additional issues are seen.

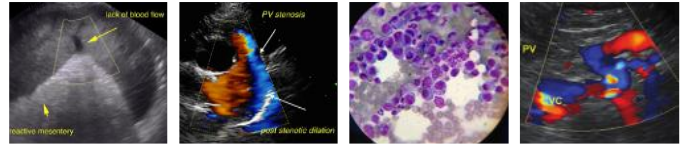
What has not been determined is the cause of collapse episodes. Single abnormal beats would not cause symptoms; however, no collapse was captured while wearing the monitor. Arrhythmic syncope is considered unlikely with this degree of abnormality. A repeat echo is recommended, given the timeframe.

Fish oil supplementation is recommended for dogs with arrhythmias (1000mg of omega 3 and 6 once to twice daily).

Plan: Monitor at home for worsening collapse, exercise intolerance, and/or lethargy and reassess in this instance. A recheck echo is recommended. If patient does well, a repeat ECG or holter is suggested in 6 months.

IMAGES





PATIENT

Froot Loop Spencer

SPECIES

Canine

BREED

Rat Terrier

SEX

MN

AGE

14 years

WEIGHT

8.8 lbs

INTERPRETED BY

Maggie Machen Lamy,
DVM, DACVIM
(Cardiology)

IMAGING PERFORMED BY

HOSPITAL NAME

WLAH

REFERRING VET

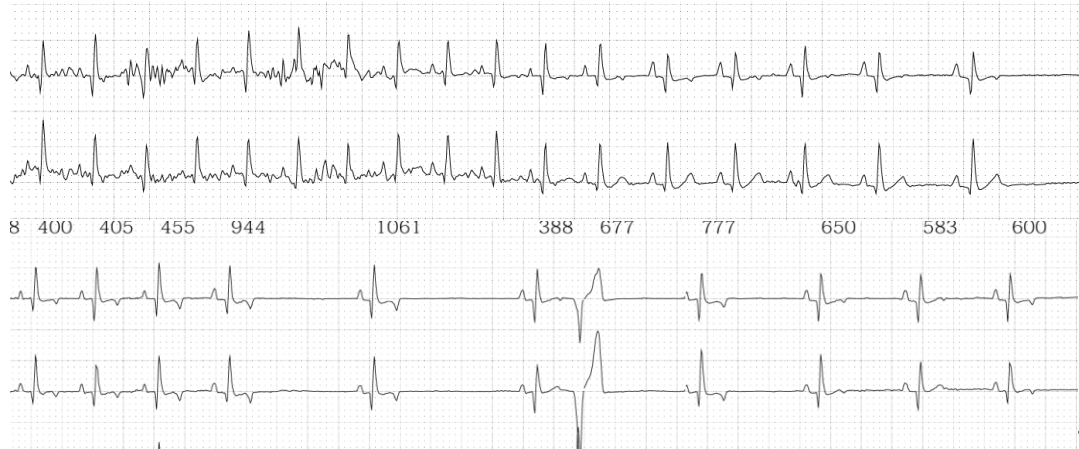Dr. Kitz

INVOICE

45923

DATE

11/25/25



The

information and recommendations provided are based on the images presented by the referring veterinarian. No evaluation can be communicated regarding pathology that was not visible in the image/video clips provided.

Thank you for this referral. If the clinical or image interpretation does not parallel your findings or if I can be of any further assistance please contact me.

Maggie Machen Lamy, DVM
Diplomate of the American College of Veterinary Internal Medicine (Cardiology)
info@sonopath.com